

Muscular Dystrophy Associated with β -Dystroglycan Deficiency

Mustafa A. M. Salih, MD,*
Yoshihide Sunada, MD, PhD,† M. Al-Nasser, MD,*
C. O. Ozo, MD,‡ M. H. S. Al-Turaiki, PhD,§
Maksood Akbar, PhD,§ and Kevin P. Campbell, PhD†

β -Dystroglycan, a 43-kd transmembrane dystrophin-associated glycoprotein, plays an important role in linking dystrophin to the laminin-binding α -dystroglycan. α -/ β -Dystroglycan is encoded by a single gene on chromosome 3p21 and ubiquitously expressed in muscle and nonmuscle tissues. No known human diseases have been mapped to this locus. Here, we describe the selective deficiency of β -dystroglycan in a 4-year-old Saudi boy with muscular dystrophy. The patient had a borderline elevation of serum creatine kinase level and early-onset proximal symmetrical muscle weakness and wasting without calf hypertrophy. The milder phenotype may suggest a secondary deficiency of β -dystroglycan; however, the unique immunofluorescence labeling suggests that the patient may present a novel form of muscular dystrophy.

Salih MAM, Sunada Y, Al-Nasser M, Ozo CO,
Al-Turaiki MHS, Akbar M, Campbell KP.
Muscular dystrophy associated with β -dystroglycan
deficiency. *Ann Neurol* 1996;40:925-928

Identification of dystrophin, the protein product of the Duchenne muscular dystrophy (DMD) gene, has led to the discovery of a large oligomeric complex of novel sarcolemmal membrane proteins: the dystrophin-glyco-

From the *Division of Pediatric Neurology, Department of Pediatrics, and †Department of Pathology, College of Medicine, King Saud University, Riyadh, Saudi Arabia; ‡The Joint Center for Research in Prosthetics and Orthotics and Rehabilitation Programmes, Riyadh, Saudi Arabia; and †Howard Hughes Medical Institute and Department of Physiology and Biophysics, University of Iowa College of Medicine, Iowa City, IA.

Received Feb 7, 1996, and in revised form May 20. Accepted for publication Jun 12, 1996.

Address correspondence to Prof Salih, Department of Pediatrics (39), College of Medicine & KKHU, King Saud University, P.O. Box 2925, Riyadh 11461, Saudi Arabia.

protein complex (DGC) [1]. This complex spans the sarcolemma of skeletal muscle fibers to provide a linkage between the cytoskeleton and the extracellular matrix [2]. Recent biochemical and molecular characterization revealed that the complex consists of three structural subcomplexes: dystroglycan complex (α - and β -dystroglycan), sarcoglycan complex (α -, β -, and γ -sarcoglycan), and the subsarcolemmal syntrophins (α -, β 1-, and β 2-) (reviewed in [3]). Dystrophin binds F-actin through its N-terminus and is also directly linked to β -dystroglycan, a transmembrane component that is tightly associated with the laminin-binding α -dystroglycan. Thus, the dystroglycan complex links laminin to the actin cytoskeleton. α -Sarcoglycan (adhalin or 50 kDa dystrophin-associated glycoprotein [DAG]), β -sarcoglycan (43DAG or A3B), and γ -sarcoglycan (35DAG), possibly with 25 kDa dystrophin-associated glycoprotein (DAP), form a sarcoglycan complex in the membrane; however, its interaction with dystroglycan or dystrophin still remains elusive.

The integrity of the cytoskeletal-extracellular linkage mediated by the DGC is important to muscle membrane stability, and loss or abnormality of certain components leads to a disruption of the linkage and causes various forms of muscular dystrophy (MD). In DMD, the absence of dystrophin leads to a secondary deficiency of all the glycoproteins which could be involved in the pathogenesis of muscle degeneration [1, 4]. Recently, primary deficiency in sarcoglycan complex (α -, β -, γ -sarcoglycan) was proved to cause limb-girdle MD [5-7] of variable severity, including severe childhood autosomal recessive muscular dystrophy (SCARMD) [8, 9], which resembles the DMD phenotype and has been attributed to adhalin (α -sarcoglycan) deficiency [5]. In addition, one of the laminin subunits, laminin α 2 chain (merosin), was found to be deficient in the classic type of congenital muscular dystrophy (CMD) [10]. Thus, so far at least five different muscular dystrophies are related to abnormalities of the DGC.

α / β -Dystroglycan is encoded by a single gene on chromosome 3p21 and a 97 kDa precursor polypeptide is cleaved and processed into α -dystroglycan (156 kDa) and β -dystroglycan (43 kDa) [2]. The tissue distribution of dystroglycan is ubiquitous in both muscle and nonmuscle tissues: Muscle dystroglycan complex is of special importance in linking the laminin α 2 chain to dystrophin [11]. In addition, Grb2 binding of β -dystroglycan suggests its potential involvement in signal transduction [12]. However, the precise role of this protein in various tissues remains to be determined. Hitherto, no known human diseases are linked to the dystroglycan gene locus.

Materials and Methods

Muscle biopsy samples from the vastus lateralis were frozen in isopentane cooled in liquid nitrogen and stored at -80°C

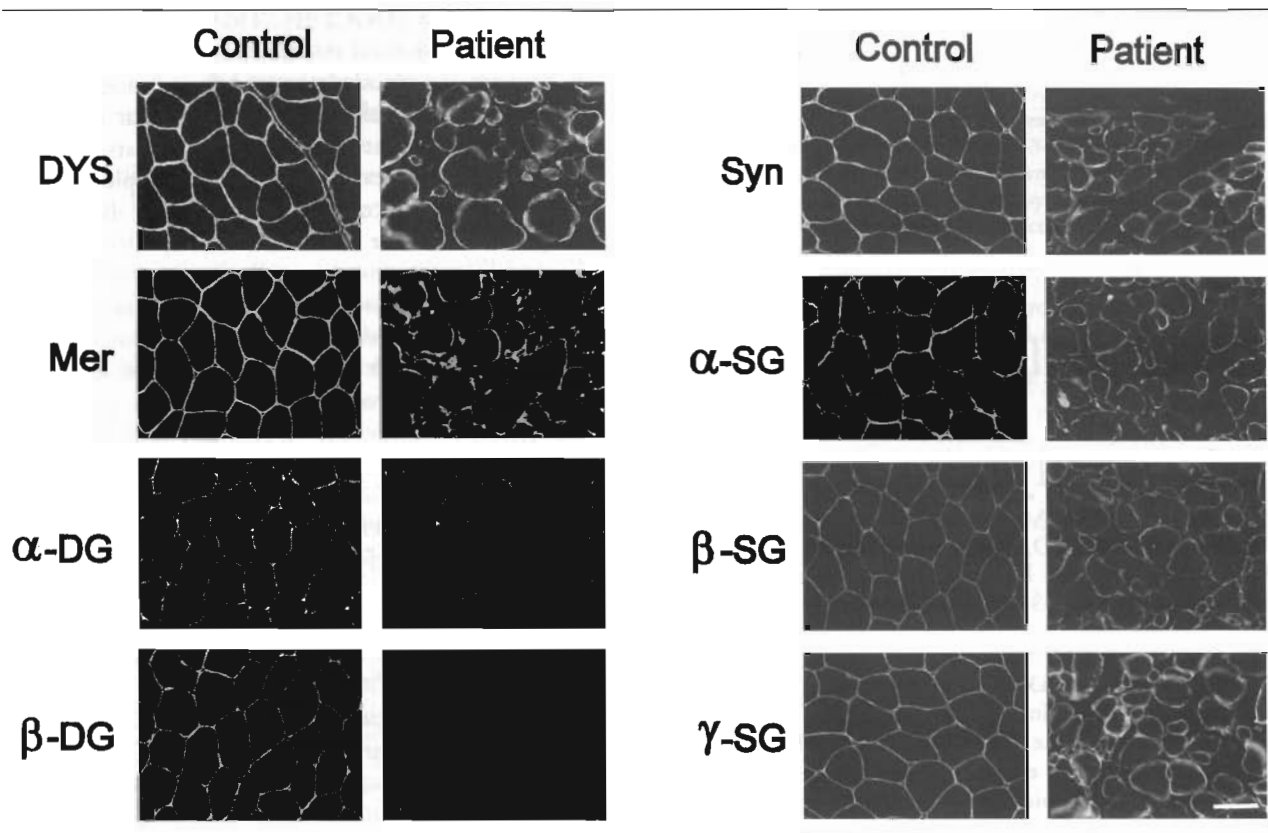


Fig 1. Immunofluorescence analysis of biopsied skeletal muscles from the control subject and the patient. Muscle cryosections were immunostained with antibodies against dystrophin (DYS), laminin $\alpha 2$ chain (Mer), α -dystroglycan (α -DG), β -dystroglycan (β -DG), syntrophins (Syn), α -sarcoglycan (α -SG), β -sarcoglycan (β -SG), and γ -sarcoglycan (γ -SG). β -Dystroglycan was selectively deficient in the patient's skeletal muscle. Bar = 50 μ m.

until use. Conventional histological and histochemical techniques were performed on 10- μ m-thick transverse cryosections. Indirect immunofluorescence analysis of dystrophin and dystrophin-associated proteins was performed on 7- μ m-thick transverse cryosections as previously described [4]. The following primary antibodies were used: monoclonal antidystrophin antibodies VIA4₂ [1] and DYS1 (Novocastra); monoclonal anti- β -dystroglycan antibody 43DAG/8D5 [13]; monoclonal anti- α -sarcoglycan antibody IVD3₁ [1]; sheep polyclonal anti-fusion protein D antibody recognizing α -dystroglycan [2]; rabbit polyclonal anti- β -sarcoglycan fusion protein antibody [6]; sheep polyclonal anti- γ -sarcoglycan antibody [7]; and sheep affinity-purified antisynthrophin antibody [5]. Sodium dodecyl sulfate (SDS) extracts from biopsied skeletal muscle were immunostained with sheep anti-fusion protein B antibody, which recognizes a core peptide of α - and β -dystroglycan as previously characterized [2].

Case History

A 4-year-old Saudi boy was referred with a complaint of abnormal gait, noticed at the age of 1½ years by the parents, and difficulty standing from the sitting position and progressive muscle weakness. He was a product of a full-term normal pregnancy and delivery and had normal early neonatal life, and his developmental milestones were within normal.

There was no evidence of consanguinity in his parents, who had 3 other children who were healthy.

On examination, he looked well with normal growth parameters and cardiovascular system. Tone was reduced in the upper and lower limbs. He could raise his hands above the head and had mild winging of the scapulae. He had symmetrical proximal muscle weakness and wasting involving both the upper and the lower limbs. Shoulder joint abductors (supraspinatus and deltoid) and pectorals were graded as 4 using the Medical Research Council (MRC) muscle power scale of 0 to 5. Hip flexors (iliopsoas) were also weak (4-), whereas hip extensors (including the glutei) were stronger (4+). No hypertrophy of calf or other muscles was observed. He could walk independently, waddling on flat feet, and had to support himself using one hand when rising from a sitting position, in a modified Gower's maneuver. Tendon jerks were hypoactive in the upper and lower limbs and sensation seemed intact.

Investigations revealed normal findings on the electrocardiogram (ECG), echocardiogram, and nerve conduction studies. Electromyography revealed myopathic changes. Serum creatine kinase, measured on two occasions, was marginally raised at 248 and 255 IU/liter (normal < 232). Magnetic resonance imaging (MRI) of the brain showed no evidence of brain malformation or increased signal intensities in the white matter on T2-weighted images.




Fig 2. Immunoblot analysis of skeletal muscle sodium dodecyl sulfate extracts from the control subject (C) and the patient (P). The blot was immunostained with anti-fusion protein B antibody recognizing both α - and β -dystroglycan (α -DG and β -DG, respectively). Molecular standards (in kilodaltons) are shown on the left.

Results

The muscle biopsy samples showed dystrophic features with type I fiber predominance but no evidence of grouping. Immunofluorescence showed normal dystrophin expression (Fig 1) and laminin α 2 chain. The expression of sarcoglycan components, α -, β -, and γ -sarcoglycan, was comparable with that of control skeletal muscle (see Fig 1). However, the immunostaining of β -dystroglycan using the 8D5 monoclonal antibody revealed a drastic reduction (see Fig 1). Interestingly, the immunostaining with anti-fusion protein D antibody demonstrated normal expression of α -dystroglycan (see Fig 1). Immunoblot analysis using anti-fusion protein B antibody also demonstrated a selective deficiency of β -dystroglycan despite the preservation of α -dystroglycan (Fig 2).

Discussion

The patient described had a myopathy that mainly affected the girdle and the proximal limb muscles starting at 1½ years of age. The dystrophic nature of the disease was revealed by the muscle biopsy studies.

Based on the clinical ground, the normal early motor development makes unlikely the diagnosis of CMD [14]. The two other forms of MD that can present at such an early age are DMD and SCARMD, the latter being more prevalent in Saudi Arabia [15]. However, the patient had no calf hypertrophy, which is a prominent feature early in the course of both DMD and SCARMD [13–16]. Also, serum CK was marginally raised, whereas in DMD its level is 100 to 300 times normal between the age of 1 and 5 years [16] and 5 to 116 times normal in SCARMD patients [17]. The ECG was normal in this patient and did not show the tall right precordial R waves in the lateral and left leads characteristic of DMD, nor did it show the ST-segment depression and T-wave changes observed in SCARMD patients [15, 16].

The important differentiating criteria were revealed by immunohistochemical analysis of the muscle biopsy samples. The normal dystrophin immunostaining excluded typical DMD or Becker's MD [18], and no deficiency of α -(adhalin), β -, or γ -sarcoglycan also excludes sarcoglycanopathy, which encompasses the SCARMD phenotype. Merosin-negative CMD was ruled out by the normal immunostaining of the laminin α 2 chain. Instead, this particular case was characterized by the selective deficiency of β -dystroglycan, which has not yet been reported in relation to any type of neuromuscular disorders.

α -/ β -Dystroglycan is encoded by a single gene and messenger RNA, and the precursor polypeptide is post-translationally processed into these two mature glycoproteins [2]. Differential expression of α - and β -dystroglycan was a striking feature of the patient's skeletal muscle. Normal expression of α -dystroglycan suggests that a small deletion or a point mutation in the β -dystroglycan coding region is a possible explanation for the differential expression of these two proteins in this patient. However, dystroglycan knock-out mice have been proved to be embryonic lethal [19], suggesting that the milder phenotype of this particular patient is unlikely due to a primary defect in the dystroglycan gene. Otherwise, a primary mutation in an unknown protein that directly interacts with β -dystroglycan and/or contributes to the stability of β -dystroglycan may cause secondary deficiency of β -dystroglycan. Interestingly, selective disappearance of β -dystroglycan was observed during the degeneration process of muscle cells that was induced by the injection of a snake venom [20]. Thus, the possible difference in the processing or turnover rate of these two glycoproteins may also explain the differential labeling.

In addition to the molecular pathogenesis of MD, the intriguing findings described here provide a clue to understanding the molecular organization of the DGC. It is extremely worthy to note the proper membrane localization of other DGC components in spite

of the deficiency of β -dystroglycan, since β -dystroglycan is believed to be crucial for linking dystrophin and α -dystroglycan to the sarcolemma. Although it is quite unlikely that the normal molecular organization of the complex is maintained without β -dystroglycan, the present finding suggests that there may be another dystrophin-anchoring site, possibly in the sarcoglycan complex. Also, there might be a direct interaction between α -dystroglycan and the sarcoglycan complex for maintaining the membrane organization of α -dystroglycan without β -dystroglycan. These interesting possibilities should be studied by further biochemical experiments.

References

1. Ervasti JM, Ohlndieck K, Kahl SD, et al. Deficiency of a glycoprotein component of the dystrophin complex in dystrophic muscle. *Nature* 1990;345:315-319
2. Ibraghimov-Beskrovnaya O, Ervasti JM, Leveille CJ, et al. Primary structure of dystrophin-associated glycoproteins linking dystrophin to the extracellular matrix. *Nature* 1992;355:696-702
3. Campbell KP. Three muscular dystrophies: loss of cytoskeleton-extracellular matrix linkage. *Cell* 1995;80:675-679
4. Ohlndieck K, Matsumura K, Ionasescu VV, et al. Duchenne muscular dystrophy: deficiency of dystrophin-associated proteins in the sarcolemma. *Neurology* 1993;43:795-800
5. Roberds SL, Leturcq F, Allamand V, et al. Missense mutations in the adhalin gene linked to autosomal recessive muscular dystrophy. *Cell* 1994;78:625-633
6. Lim LE, Duclos F, Broux O, et al. β -Sarcoglycan: characterization and role in limb-girdle muscular dystrophy linked to 4q12. *Nature Genet* 1995;11:257-265
7. Jung D, Leturcq F, Sunada Y, et al. Absence of γ -sarcoglycan (35DAG) in autosomal recessive muscular dystrophy linked to chromosome 13q12. *FEBS Lett* 1996;381:15-20
8. Salih MAM. Unusual muscular dystrophy in an extended Sudanese kindred. Master of Pediatrics and Child Health thesis. University of Khartoum, 1980
9. Ben Hamida M, Fardeau M. Severe autosomal recessive limb-girdle muscular dystrophies frequent in Tunisia. In: Angelini C, Danieli GA, Fontanari D, eds. *Muscular dystrophy research: advances and new trends*. Amsterdam: Excerpta Medica, 1980: 143-146
10. Tomé FMS, Evangelista T, Leclerc A, et al. Congenital muscular dystrophy with merosin deficiency. *C R Acad Sci Paris* 1994;317:351-357
11. Sunada Y, Bernier SM, Kozak CA, et al. Deficiency of merosin in dystrophic *dy* mice and genetic linkage of laminin M chain gene to *dy* locus. *J Biol Chem* 1994;269:13729-13732
12. Yung D, Yang B, Meyer J, et al. Identification and characterization of the dystrophin anchoring site on β -dystroglycan. *J Biol Chem* 1995;270:27305-27310
13. Cullen MJ, Walsh J, Nicholson LVB. Immunogold localization of the 43-kDa dystroglycan at the plasma membrane in control and dystrophic human muscle. *Acta Neuropathol (Berl)* 1994; 87:349-354
14. Dubowitz V. Workshop report; 22nd ENMC sponsored workshop on congenital muscular dystrophy held in Baarn, the Netherlands, 14-16 May 1993. *Neuromusc Disord* 1994;4:75-81
15. Salih MAM, Mahdi A, Al-Rikabi AC, et al. Clinical and molecular pathological features of childhood autosomal recessive muscular dystrophy in Saudi Arabia. *Dev Med Child Neurol* 1996;38:262-270
16. Gardner-Medwin D, Walton J. The muscular dystrophies. In: Walton J, Karpati G, Hilton-Jones D, eds. *Disorders of voluntary muscle*. Edinburgh: Churchill Livingstone, 1994:543-594
17. Salih MAM, Omer MIA, Bayoumi RA, et al. Severe autosomal recessive muscular dystrophy in an extended Sudanese kindred. *Dev Med Child Neurol* 1983;25:43-52
18. Hoffman EP, Fischbeck KH, Brown RH, et al. Characterization of dystrophin in muscle-biopsy specimens from patients with Duchenne's or Becker's muscular dystrophy. *N Engl J Med* 1988;318:1363-1368
19. Williamson R, Ibraghimov-Beskrovnaya O, Hrstka R, et al. Inactivation of the murine dystroglycan gene produces an early midgestation embryonic lethal. *Am J Hum Genet* 1995; 57(suppl):A12
20. Vater R, Harris JB, Anderson LVB, et al. The expression of dystrophin-associated glycoproteins during skeletal muscle degeneration and regeneration. An immunofluorescence study. *J Neuropathol Exp Neurol* 1995;54:557-569