

Laminin Abnormality in Severe Childhood Autosomal Recessive Muscular Dystrophy

HIROKI YAMADA, FERNANDO M. S. TOMÉ, ITSURO HIGUCHI, HISAOMI KAWAI, KEMAL AZIBI, MALIKA CHAOUCH, STEVEN L. ROBERDS, TAKESHI TANAKA, SACHIKO FUJITA, TAKAO MITSUI, HIDETOSHI FUKUNAGA, KAZUO MIYOSHI, MITSUHIRO OSAME, MICHEL FARDEAU, JEAN-CLAUDE KAPLAN, TERUO SHIMIZU, KEVIN P. CAMPBELL, AND KIICHIRO MATSUMURA

Department of Neurology and Neuroscience, Teikyo University School of Medicine, Itabashi-ku, Tokyo, Japan; INSERM U.153, Paris, France; Third Department of Internal Medicine, Faculty of Medicine, Kagoshima University, Kagoshima, Japan; First Department of Internal Medicine, School of Medicine, University of Tokushima, Tokushima, Japan; Laboratoire de Biologie, Hôpital de Bologhine and Service de Neurologie, Hôpital de Ben Aknoun, Algiers, Algeria; Howard Hughes Medical Institute and Department of Physiology and Biophysics, University of Iowa College of Medicine, Iowa City, Iowa; Saitama Red Cross Blood Center, Yono, Saitama, Japan; Department of Neurology, National Minamikyushyu Hospital, Kajiki-cho, Aira-gun, Kagoshima, Japan; and INSERM U.129, Institut Cochin de Génétique Moléculaire, Paris, France

BACKGROUND: In skeletal muscle, dystrophin exists in a large oligomeric complex tightly associated with several novel sarcolemmal proteins, including the 50-kDa transmembrane glycoprotein called adhalin. The dystrophin-glycoprotein complex links the subsarcolemmal actin cytoskeleton to the basal lamina component laminin, thus providing stability to the sarcolemma. Disturbance of this linkage due to the absence of dystrophin plays a crucial role in the molecular pathogenesis of muscle fiber necrosis in Duchenne muscular dystrophy. Severe childhood autosomal recessive muscular dystrophy (SCARMD) is similar to Duchenne muscular dystrophy in phenotype but is characterized by the deficiency of adhalin. At present, the status of the link between the dystrophin-glycoprotein complex and laminin is unclear in SCARMD.

EXPERIMENTAL DESIGN: We investigated, by immunohistochemistry using confocal laser scanning microscopy, the status of the expression of laminin subunits, A, M, B1, B2, and S chains, in skeletal muscle biopsy specimens of eight SCARMD patients from various human populations. In addition, we correlated the severity of laminin abnormality with the severity of both clinical symptoms and histopathologic changes in these patients.

RESULTS: The reduction of laminin B1 chain and the overexpression of the S chain, a homologue of B1, in the extrajunctional basal lamina were observed in the five patients who had advanced clinical symptoms and histopathologic changes. Abnormalities in the expression of laminin were not observed in the three less affected patients.

CONCLUSIONS: The expression of laminin is greatly disturbed in severely diseased SCARMD muscle deficient in adhalin. Disturbance of sarcolemma-basal lamina interaction may play an important role in the molecular pathogenesis of muscle fiber necrosis in SCARMD.

Additional key words: Duchenne muscular dystrophy, Dystrophin, Dystrophin-glycoprotein complex, Merosin, Basal lamina, Confocal laser scanning microscopy.

A severe form of autosomal recessive muscular dystrophy closely resembling Duchenne/Becker muscular dystrophy (DMD/BMD) in phenotype has been obscure as a clinical entity until recently. This obscurity is partly because of its rarity in most human populations and partly because autosomal recessive inheritance was difficult to demonstrate in any given family (1). A number of investigators presumed, however, the existence of this form of muscular dystrophy from the

occasional observation of apparent DMD/BMD in girls or in siblings including both boys and girls (2, 3). A similar disease affecting Japanese patients was reported as malignant limb-girdle type (4). The existence of this form of muscular dystrophy was confirmed by the detailed description of 93 affected Tunisian children by Ben Hamida *et al.* in 1983 (5). Although clinical features were similar to those reported by other investigators, they clearly delineated a few important

differences from DMD/BMD, including the absence of mental retardation and heart involvement, that were not consistently documented in the previous reports (5). This disease is now considered to be prevalent in North Africa and in the Middle East and is referred to as severe childhood autosomal recessive muscular dystrophy (SCARMD) (Mendelian Inheritance in Man number 253700) (6, 7). Dystrophin, the protein product of the DMD gene (8), was shown to be normally expressed in muscle biopsy specimens from Tunisian patients, thus confirming the difference of this disease from DMD/BMD at the protein level (9).

In skeletal muscle, dystrophin exists in a large oligomeric complex tightly associated with several novel sarcolemmal proteins, including the 50-kDa transmembrane glycoprotein called adhalin (10–15). α -dystroglycan, an extracellular dystrophin-associated glycoprotein of 156 kDa, binds laminin, a major structural component of the inner basal lamina (14, 16). At the cytoplasmic side of the dystrophin-glycoprotein complex (DGC), dystrophin interacts with the subsarcolemmal actin cytoskeleton (16–18). This complex is therefore presumed to provide a trans-sarcolemmal linkage between the basal lamina and the subsarcolemmal cytoskeleton (13, 14, 16). Recently, we have demonstrated the deficiency of adhalin in the skeletal muscle of one Lebanese and three Algerian patients afflicted with SCARMD (19). Subsequently, the deficiency of adhalin has been demonstrated in non-Arab patients presenting with SCARMD phenotype, thereby suggesting that adhalin deficiency may be the common molecular feature of SCARMD in various human populations (20–25). SCARMD with adhalin deficiency is genetically heterogeneous; two loci have been identified thus far (20, 22, 23, 26, 27). Tunisian and Algerian families have been linked to chromosome 13q, and a large French family has recently been linked to the adhalin gene on chromosome 17q (20, 26, 27). These findings suggest that the genetic background of SCARMD may vary among different human populations. Adhalin is also greatly reduced in DMD patients (11, 28), so we hypothesized that the deficiency of adhalin might play a crucial role in the molecular pathogenesis of both DMD and SCARMD (19). However, the precise mechanism by which the deficiency of

adhalin leads to muscle fiber necrosis in SCARMD remains unknown.

Laminin is a major structural component of the basal lamina, which is involved in a number of important biologic functions, including cell adhesion, migration, proliferation, and differentiation (29, 30). The prototypical laminin molecule is a cruciform heterotrimer comprised of three distinct chains of classes A, B1, and B2 (29, 30). Each class of laminin chains have multiple isoforms, and laminin exists in various trimers having diverse biologic functions in different tissues (30, 31). In skeletal muscle, merosin, a laminin variant that contains the M chain instead of A, is expressed in the basal lamina surrounding muscle fibers (32, 33). Recently, we reported two Japanese patients with the phenotype of SCARMD who were deficient in adhalin (34). In these patients, the B1 chain was greatly reduced in the basal lamina, raising a possibility that the deficiency of adhalin may be associated with abnormality in the expression of laminin (34).

At present, it is unknown if laminin B1 chain is reduced in all SCARMD patients irrespective of racial/geographical background or progression of the disease. Also unknown are the role of B1 reduction in the pathologic process leading to muscle fiber necrosis in SCARMD and the composition of the laminin heterotrimer in which the B1 chain is specifically reduced. In the present study, we investigated, by immunohistochemical analysis using confocal laser scanning microscopy (cLSM), the status of the expression of laminin subunits in skeletal muscle of SCARMD patients from various human populations.

EXPERIMENTAL DESIGN

We investigated, by immunohistochemistry using cLSM, the status of the expression of laminin subunits, A, M, B1, B2, and S chains, in skeletal muscle biopsy specimens of eight SCARMD patients from various human populations (Table 1). In addition, we correlated the severity of laminin abnormality with the severity of both clinical symptoms and histopathologic changes in these patients. Genetic analysis of the adhalin gene has not yet been performed for these patients.

TABLE 1. SUMMARY OF PATIENT PROFILES AND RESULTS OF IMMUNOHISTOCHEMISTRY

| Patient Number | Racial Background | Sex | Consanguinity | Onset (yr) | Biopsy (yr) | Loss of Walk (yr) or Clinical Status at Biopsy Time | Status of Laminin Expression | | Histopathologic Changes |
|----------------|-------------------|-----|---------------|------------|-------------|---|------------------------------|------------------------|-------------------------|
| | | | | | | | B1 Chain Deficiency | S Chain Overexpression | |
| 1 | Algerian | F | ? | 8 | 19 | 19 | Moderate | Mild | Moderate |
| 2 | Algerian | F | + | 7 | 14 | 14 | Moderate | Moderate | Severe |
| 3 | Algerian | F | + | 6 | 11 | Ambulatory | Normal | Normal | Mild |
| 4 | French | F | – | 13 | 28 | Ambulatory | Normal | Normal | Borderline |
| 5 | French/Arab | M | + | 3 | 15 | 15 | Severe | Mild | Severe |
| 6 | Japanese | M | + | 10 | 41 | 21 | Mild | Mild | Moderate |
| 7 | Japanese | M | + | 5 | 30 | 13 | Moderate | Moderate | Severe |
| 8 | Japanese | F | + | 3 | 11 | Ambulatory | Normal ^a | Normal ^a | Moderate ^a |

^a Detailed analysis of laminin expression was not possible because of storage artifact of the biopsied muscle specimen in this patient. However, the apparent immunostaining intensity of laminin B1 and S chains in the extrajunctional basal lamina was indistinguishable from that of healthy humans. Hematoxylin and eosin staining had been performed 20 yr before this study.

RESULTS AND DISCUSSION

Compared with normal humans, dystrophin, α/β -dystroglycan, and the 59-kDa dystrophin-associated protein were well preserved (not shown), but adhalin was drastically reduced in the sarcolemma in the eight SCARMD patients (Patients 1 to 8) (Figs. 1 and 2). The reduction of adhalin in these patients was more severe than in DMD patients (Fig. 1). The 35-kDa dystrophin-associated glycoprotein was moderately reduced in the sarcolemma of the eight patients (not shown). These features are identical to those observed in SCARMD patients reported previously (19–21, 23–25, 27).

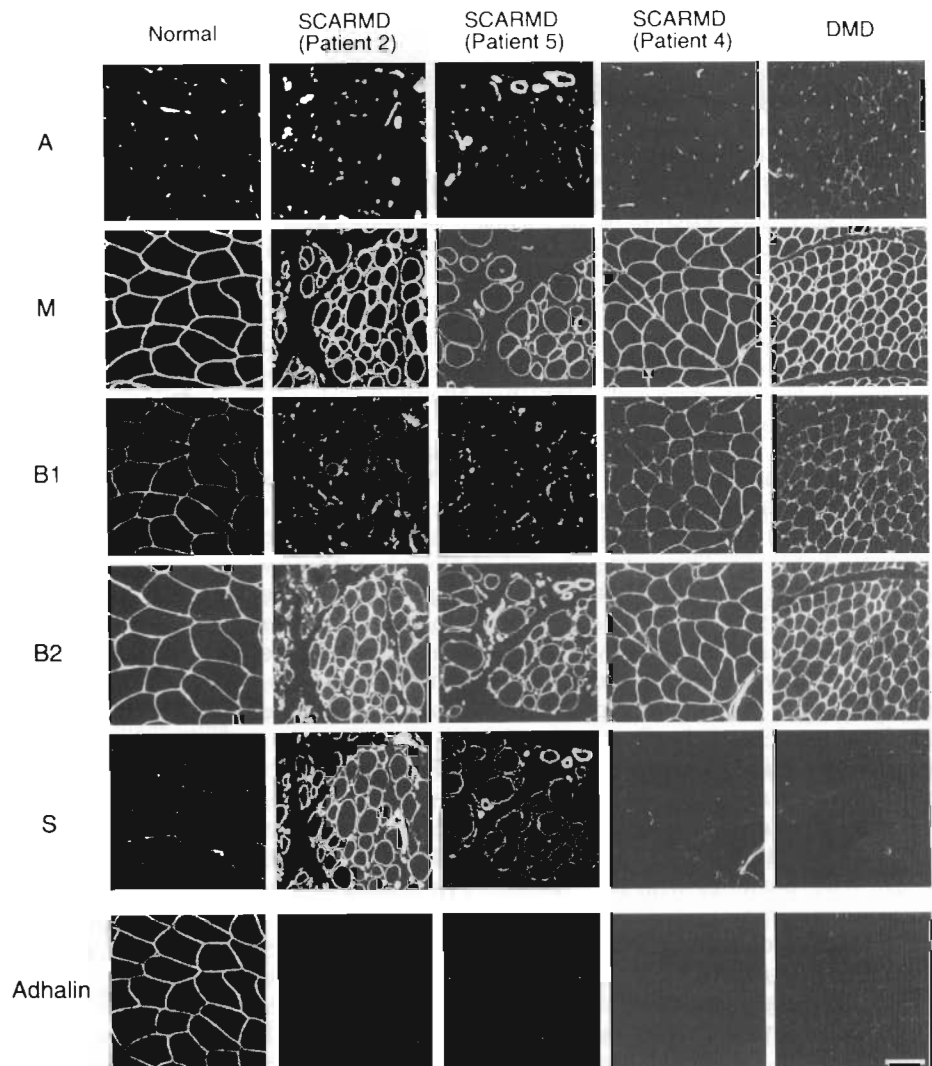
In normal humans, immunoreactivity for laminin M, B1, and B2 chains was detected in the basal lamina surrounding muscle fibers (Fig. 1). Immunoreactivity for the A and S chains was detected around blood vessels but was not detectable in the extrajunctional basal lamina (Figs. 1 and 2). In DMD patients, immunoreactivity for the A chain was clearly detectable in the extrajunctional basal lamina, whereas immunoreactivity for the M, B1, B2, and S chains was indistinguishable from that of normal humans (Fig. 1). In Patients 1, 2, 5, 6, and 7, immunoreactivity for the B1

chain was greatly reduced, and immunoreactivity for the S chain was clearly detectable in the extrajunctional basal lamina (Figs. 1 and 2). Immunoreactivity for the A, M, and B2 chains was indistinguishable from that of normal humans or DMD patients (Fig. 1). In Patients 3, 4, and 8, on the other hand, abnormalities in the immunoreactivity for laminin subunits were not observed (Fig. 1).

In the skeletal muscle of Patient 7, adhalin was preserved, although greatly reduced, in an irregular and patchy distribution along the sarcolemma (Fig. 3). In this patient, double immunostaining analysis could be performed using anti-adhalin and anti-laminin B1 chain Ab and revealed the colocalization of the immunoreactivity for the residual adhalin and B1 along the sarcolemma (Fig. 3). In the other patients, the deficiency of adhalin was so severe that definite results could not be obtained concerning the colocalization of the residual adhalin and B1 by double immunostaining analysis.

It was noteworthy that all five SCARMD patients with the reduction of the B1 chain (Patients 1, 2, 5, 6, and 7) were already confined to wheelchair or bed at

FIG. 1. Immunohistochemical analysis of laminin subunits in non-Japanese SCARMD patients (Patients 2, 4 and 5): a normal human and a DMD patient. Indirect immunofluorescence of serial cryosections was performed using mAb against adhalin and laminin A, M, B1, B2, and S chains. Optical slice images were obtained using cLSM. Immunoreactivity for adhalin was detected in the sarcolemma in a normal human, whereas it was greatly reduced in a DMD patient and in Patients 2, 4, and 5. The reduction of adhalin in Patients 2, 4, and 5 was more severe than in a DMD patient. In a normal human, immunoreactivity for the M, B1, and B2 chains was detected in the basal lamina surrounding muscle fibers. Immunoreactivity for the A and S chains was detected around blood vessels but was not detectable in the extrajunctional basal lamina. In a DMD patient, immunoreactivity for the A chain was clearly detectable in the extrajunctional basal lamina, whereas immunoreactivity for the M, B1, B2, and S chains was indistinguishable from that of a normal human. In Patients 2 and 5, immunoreactivity for the B1 chain was greatly reduced, and immunoreactivity for the S chain was clearly detectable in the extrajunctional basal lamina. Immunoreactivity for the A, M, and B2 chains was indistinguishable from that of a normal human or a DMD patient. Similar findings were observed in Patient 1 (not shown). In Patients 3 (not shown) and 4, abnormalities in the immunoreactivity for the laminin subunits were not observed. Bar, 100 μ m.



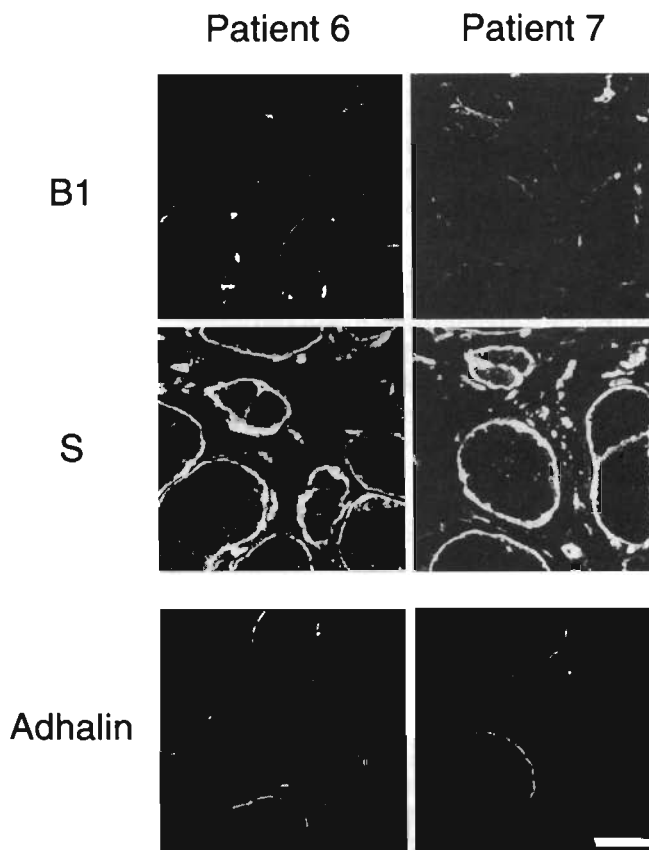


FIG. 2. Immunohistochemical analysis of laminin B1 and S chains in Japanese patients with SCARM (Patients 6 and 7). Indirect immunofluorescence of serial cryosections was performed using mAb against adhalin and laminin B1 and S chains. Optical slice images were obtained using cLSM. In Patients 6 and 7, who were deficient in adhalin, immunoreactivity for the B1 chain was greatly reduced, and immunoreactivity for the S chain was clearly detectable in the extrajunctional basal lamina. Immunoreactivity for the A, M, and B2 chains was indistinguishable from that of a normal human (not shown). In Patient 8, gross abnormalities in the immunoreactivity for laminin subunits were not observed, although adhalin was deficient in the sarcolemma (not shown). Bar, 50 μ m.

the time of muscle biopsy, whereas the three patients with apparently normal expression of laminin (Patients 3, 4, and 8) could still walk at the time of muscle biopsy (Table 1). This suggested that the abnormality in laminin expression might reflect progression of the disease. To know the correlation between the reduction of the B1 chain and the severity of the histopathologic changes, conventional histopathologic analysis of biopsied skeletal muscle was performed (Table 1). In the skeletal muscle of the five patients with the reduction of the B1 chain (Patients 1, 2, 5, 6, and 7), variation in muscle fiber size and proliferation of interstitial connective tissue in the perimysium and endomysium were moderate to great (Fig. 4). In the skeletal muscle of the two patients who had normal expression of the B1 chain (Patients 3 and 4), however, the cytoarchitecture of muscle fibers was relatively well preserved, and variation in muscle fiber size and proliferation of interstitial connective tissue were mild (Fig. 4). In Patient 8, who had apparently normal expression of the B1 chain (Table 1), variation in muscle fiber size

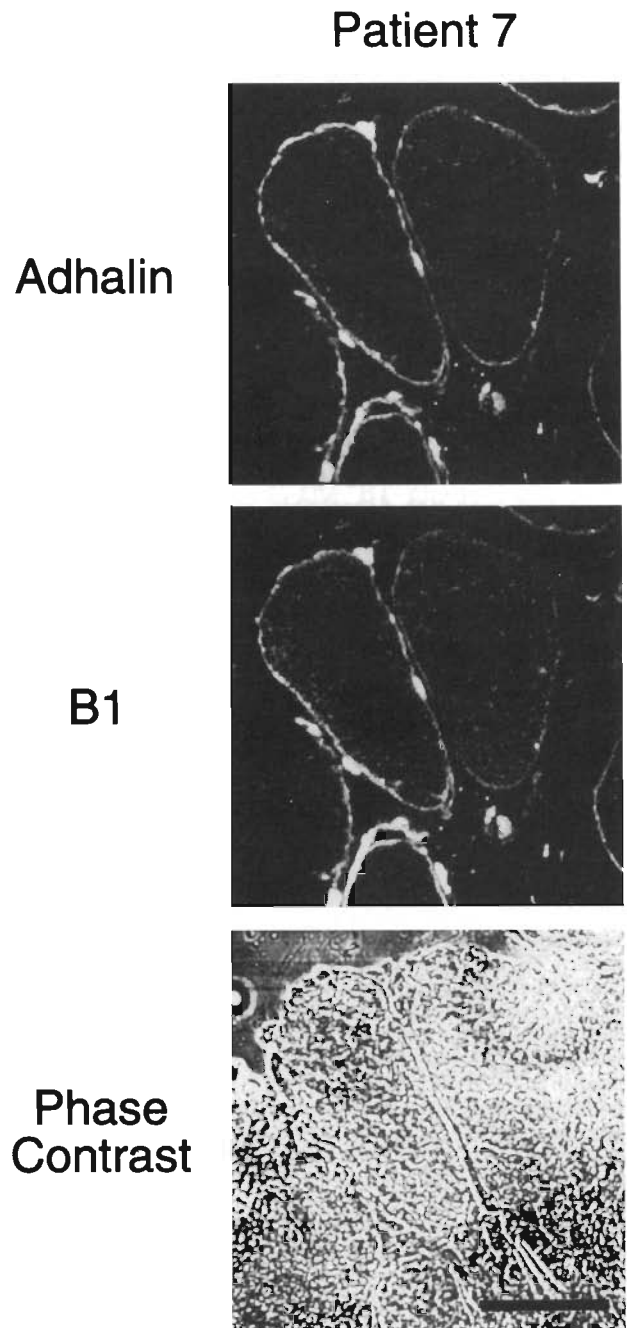


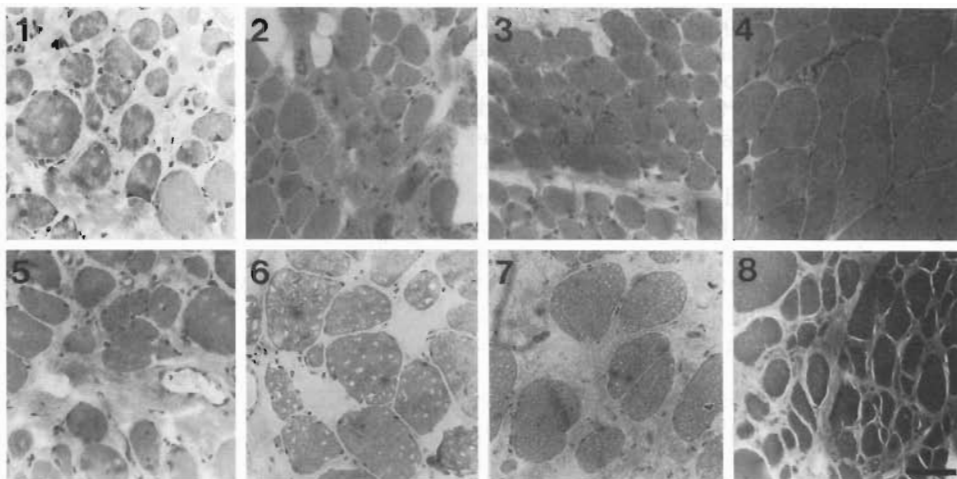
FIG. 3. Double immunostaining analysis of laminin B1 chain and adhalin in a Japanese patient with SCARM (Patient 7). Laminin B1 chain was detected by incubation with anti-B1 mAb 4E10 followed by incubation with rhodamine-conjugated anti-mouse IgG Ab. Adhalin was detected by incubation with affinity-purified sheep anti-adhalin Ab followed by incubation with biotin-conjugated rabbit anti-sheep IgG Ab and FITC-conjugated streptavidin. Adhalin was preserved, although greatly reduced, in a patchy and irregular distribution in the sarcolemma in the muscle fibers shown in this panel. Immunoreactivity for the residual B1 and adhalin was colocalized along the sarcolemma in these muscle fibers. Bar, 50 μ m.

and proliferation of interstitial connective tissue were moderate (Fig. 4).

DISCUSSION

Laminin is a cross-shaped molecule that has three short arms made up of one each of three chains of

FIG. 4. Histopathologic analysis of biopsied skeletal muscle from SCARMD patients. Cryosections were stained with hematoxylin and eosin. In the skeletal muscle of Patients 1, 2, 5, 6, and 7 with the reduction of laminin B1 chain, variation in muscle fiber size and proliferation of interstitial connective tissue were moderate to great in the perimysium and endomysium. In the skeletal muscle of Patients 3 and 4, who had apparently normal expression of the B1 chain, cyto-architecture of muscle fibers was relatively well preserved, and variation in muscle fiber size and proliferation of interstitial connective tissue were mild. In Patient 8, who had apparently normal expression of the B1 chain, variation in muscle fiber size and proliferation of interstitial connective tissue were moderate. Bar, 50 μ m.



classes A, B1, and B2 and one long arm made up of all three chains (30, 31). The long arm has a large globular domain at its distal end that is made up of a portion of the A chain (or M in the case of merosin) (29). α -dystroglycan binds to this globular domain of the distal long arm of laminin (16, 35). In skeletal muscle, the M chain is expressed in both junctional and extrajunctional basal lamina, whereas the A chain is expressed only in the neuromuscular junction (31–33). The B1 chain is expressed in the extrajunctional basal lamina but is absent in the neuromuscular junction, whereas the S chain, a homologue of B1, is expressed only in the junctional basal lamina (33, 36). The B2 chain is distributed throughout the basal lamina surrounding both junctional and extrajunctional sarcolemma (33). Hence, laminin exists as merosin (M/B1/B2) in the extrajunctional basal lamina and as either s-laminin (A/S/B2) or s-merosin (M/S/B2) in the junctional basal lamina.

In the present study, we demonstrate that the expression of two laminin subunits, the B1 and S chains, is greatly disturbed in the skeletal muscle of the SCARMD patients who have advanced clinical symptoms and histopathologic changes, irrespective of racial/geographical differences. Our results thus suggest that the abnormality in the expression of laminin subunits may correlate with the progression of the disease. It is unknown if our findings may reflect differences in the underlying genetic defects, because it is unclear at present if all of the SCARMD patients reported here have the same genetic defects.

Recently, Hayashi *et al.* investigated the status of the expression of laminin subunits in various neuromuscular disorders (37). They reported the expression of the A chain in the extrajunctional basal lamina in DMD patients and the great reduction of the M chain accompanied by the expression of the A chain in the extrajunctional basal lamina in the patients afflicted with Fukuyama-type congenital muscular dystrophy (FCMD), a severe autosomal recessive muscular dystrophy prevalent in Japan (37). In other neuromuscular diseases, they did not find gross abnormalities in laminin expression (37). Subsequently, Tomé *et al.*

demonstrated the absence of the M chain in a subset of European patients afflicted with congenital muscular dystrophy (CMD) (38). Taken together with the previous reports that α -dystroglycan is greatly reduced in DMD muscle (11, 28) and is expressed abnormally in skeletal muscle from some patients with Fukuyama-type congenital muscular dystrophy (39), these findings suggest that the disturbance of the interaction between α -dystroglycan and the M chain may play important roles in the molecular pathogenesis of several forms of muscular dystrophies.

At present, the cause of the distorted expression of laminin subunits in severely diseased SCARMD muscle remains unclear, but the elucidation of its mechanism may provide insight into the molecular pathogenesis of this disease. Recently, adhalin was shown to be a transmembrane protein with an extracellular domain that has limited structural homology with entactin/nidogen, an adhesive protein in the basal lamina, and the epidermal growth factor (EGF)-like region of nerve growth factor receptors (15). Interesting to note, entactin/nidogen, which itself contains EGF-like motifs, interacts with a single EGF-like motif of the B2 chain among many EGF-like sequences present in the B1 and B2 chains (40). In addition, the B1 chain, but not M/A or B2, was immunoprecipitated from the solubilized myotube extracts by an Ab against dystrophin (41). Taken together, our results raise an intriguing possibility that, in addition to α -dystroglycan, adhalin itself may directly interact with the component(s) of the basal lamina, including laminin B1 chain.

Laminin lacking one of its three constituent subunits may not exist as a heterotrimer and may lose its function as a structural component of the basal lamina (42). Our results showing the reduction of the B1 chain accompanied by the overexpression of the S chain raise a possibility that, instead of merosin, s-merosin might be expressed in the extrajunctional basal lamina in the severely diseased SCARMD muscle. However, the immunostaining intensity for the S chain did not correlate strictly with the reduction of B1 (Table 1). It is thus only speculative whether the S chain indeed

replaces B1, without biochemical data showing the composition of the laminin heterotrimer in SCARMD muscle. Furthermore, a recent study indicates that biochemical properties of merosin and s-merosin are similar in many aspects but also differ slightly (43). This suggests that the reduction of the B1 chain may not be compensated completely by S overexpression. In any case, further biochemical research is needed to clarify the putative interaction between adhalin and the component(s) of the basal lamina and the mechanism by which the deficiency of adhalin leads to the abnormality in the expression of laminin subunits in the basal lamina.

Table 2 summarizes the results of the recent studies on the expression of dystrophin, dystrophin-associated proteins, and laminin subunits in various muscular dystrophies (9, 11, 19, 28, 37–39, 44–50). In conclusion, the results of the present and recent studies suggest that the disruption of the linkage between the subsarcolemmal actin cytoskeleton and laminin in the basal lamina *via* the DGC may be a common mechanism leading to muscle fiber necrosis in several forms of severe muscular dystrophies. The breakdown of this linkage may cause the instability of the sarcolemma and may eventually lead to muscle fiber necrosis and devastating clinical symptoms.

METHODS

PATIENTS

We investigated skeletal muscle biopsy specimens from eight SCARMD patients (Table 1). Of these patients, three were Algerian, three were Japanese, one was French, and one was a child of Arab and French parents. Patients 6 and 7 were reported in detail elsewhere (34).

ANTIBODIES

mAb 2G9 against human M chain, 11D5 against human A chain, 4E10 against human B1 chain, and 2E8 against human B2 chain of laminin were purchased from GIBCO (Gaithersburg, MD). mAb C4 against bovine S chain was obtained from the Developmental Studies Hybridoma Bank maintained by the Department of Pharmacology and Molecular Sciences, Johns Hopkins University School of Medicine Baltimore, MD, and the Department of Biological Sciences, University of Iowa, Iowa City, IA, under contract N01-HD-

6–2915 from the National Institute of Child Health and Human Development. A mouse mAb IVD3₁ and affinity-purified sheep polyclonal Ab against adhalin were characterized previously (11, 19). FITC- or rhodamine-conjugated goat anti-mouse IgG Ab, biotinylated rabbit anti-sheep IgG Ab, and FITC-conjugated streptavidin were purchased from Boehringer Mannheim (Mannheim, Germany), Vector Laboratories (Burlingame, CA), and Biomedica (Foster City, CA), respectively.

IMMUNOHISTOCHEMICAL ANALYSIS USING CONFOCAL LASER SCANNING MICROSCOPY

Cryosections (7 to 8 μm) of skeletal muscle biopsy specimens were placed on SuperFrost/Plus slides (Fisher Scientific, Orangeburg, NY), air-dried for 30 minutes, and blocked with 5% BSA in PBS, pH 7.4. The sections were incubated with the primary Ab diluted in 5% BSA-PBS for 2 hours. Working dilutions of the primary Ab are as follows; 2G9, 1:1000; 11D5, 1:5000; 4E10, 1:1000; 2E8, 1:200; C4, 1:500, and IVD3₁, 1:50. After extensive wash with PBS, the sections were incubated with FITC-anti-mouse IgG Ab (1:200 in 5% BSA-PBS) for 1 hour. The sections were again washed with PBS and then mounted under coverslips with FITC-Guard (Testog, Chicago, IL). Double immunostaining analysis was performed using mouse mAb 4E10 (1:1000 in 5% BSA-PBS) and affinity-purified sheep anti-adhalin Ab (1:20 in 5% BSA-PBS) as primary Ab. Rhodamine-conjugated goat anti-mouse IgG Ab (1:100 in 5% BSA-PBS) and biotinylated rabbit anti-sheep IgG Ab (1:500 in 5% BSA-PBS) followed by FITC-streptavidin (1:1000 in 5% BSA-PBS) were used to detect immunoreaction. cLSM was used to obtain detailed images without out-of-focus artifacts and to determine fluorescent intensity with digital value. Specimens were observed and fluorescent images were obtained on a Zeiss cLSM model LSM 310, using an argon ion laser ($\lambda = 488 \text{ nm}$). For double staining analysis, a helium-neon laser ($\lambda = 543 \text{ nm}$) was used to detect fluorescence from rhodamine. To collect information through the whole thickness of the specimens, a series of 10 optical slices/field was taken at the z interval of 0.7 to 0.8 μm , and one of these slices that showed the most intense fluorescence signal was picked up to evaluate the expression of respective laminin subunits. For conventional histopathologic observation, specimens were stained with hematoxylin and eosin. Immunoblot analysis of the components of the DGC and laminin subunits was not possible because of the small size of muscle biopsy specimens.

Date of acceptance: December 2, 1994.

TABLE 2. ABNORMALITIES OF DYSTROPHIN, DYSTROPHIN-ASSOCIATED PROTEINS (DAPs), AND LAMININ/MEROSIN IN MUSCULAR DYSTROPHIES

| | Dystrophin (Subsarcolemmal Cytoskeleton) | DAPs (Sarcolemma) | Laminin/Merosin (Basal Lamina) |
|--------------------------------------|---|--|---|
| DMD ^a | Absent | Greatly reduced | A Overexpressed |
| Symptomatic DMD Carrier ^b | Mosaic | Mosaic | Unknown |
| BMD ^c | Patchy/reduced | Patchy/reduced | Unknown |
| FCMD ^d | Abnormally expressed (in some patients) | Abnormally expressed (in some patients) | M greatly reduced; A overexpressed |
| CMD ^e (a subset) | Normal | Normal | M absent; A overexpressed |
| SCARMD ^f | Normal | Adhalin deficient (35DAG reduced) | B1 greatly reduced; S overexpressed (in some patients) |

^a Represented by references 11, 28, 37, 44, and 48.

^b Represented by references 45 and 50.

^c Represented by references 44, 47, and 49.

^d Represented by references 37, 39, 44, and 46.

^e Represented by reference 38.

^f Represented by references 9, 19, and this paper.

Kevin P. Campbell is an Investigator of the Howard Hughes Medical Institute. Steven L. Roberds is supported by a Muscular Dystrophy Association Neuromuscular Disease Research Fellowship. This work was also supported by the Muscular Dystrophy Association (America), the Association Française contre les myopathies (France), a grant from Ichiro Kanahara Foundation, a grant from Nakatomi Foundation, a grant from the Science Research Promotion Fund from Japan Private School Promotion Foundation, Research Grant (5A-2) for Nervous and Mental Disorders from the Ministry of Health and Welfare, and Grants-in-Aid for Scientific Research on Priority Areas for Scientific Research (05454262, 06454280, 06670670, 06770463) and for Scientific Research on Developmental Areas (05557037) from the Ministry of Education, Science, and Culture (Japan).

Address reprint requests to: Kiichiro Matsumura, Department of Neurology, Teikyo University School of Medicine, 2-11-1 Kaga, Itabashi-ku, Tokyo 173, Japan.

REFERENCES

- Walton JN, Gardner-Medwin D. Progressive muscular dystrophy and the myotonic disorders. In: Walton SJ, editor. Disorders of voluntary muscle. New York: Churchill Livingstone Inc., 1981:481-524.
- Penn AS, Lisak RP, Rowland LP. Muscular dystrophy in young girls. *Neurology* 1970;20:147-59.
- Gardner-Medwin D, Johnston HM. Severe muscular dystrophy in girls. *J Neurol Sci* 1984;64:79-87.
- Miyoshi K, Saijo K, Kuryu Y, Yoshimatu M, Oshima Y, Nakano M, *et al.* Proposal of "malignant limb-girdle" type progressive muscular dystrophy (abstract). *Clin Neurol (Tokyo)* 1966;6:491.
- Ben Hamida M, Fardeau M, Attia N. Severe childhood muscular dystrophy affecting both sexes and frequent in Tunisia. *Muscle Nerve* 1983;6:469-80.
- Salih MAM, Omer MIA, Bayoumi RA, Karrar O, Johnson M. Severe autosomal recessive muscular dystrophy in an extended Sudanese kindred. *Dev Med Child Neurol* 1983;25:43-52.
- McKusick VA. Muscular dystrophy, Duchenne-like [Duchenne-like autosomal recessive muscular dystrophy]. In: McKusick VA, editor. Mendelian inheritance in man. Catalogs of autosomal dominant, autosomal recessive, and X-linked phenotypes. Baltimore: Johns Hopkins University Press, 1992:1566-7.
- Hoffman EP, Brown RH, Kunkel LM. Dystrophin: the protein product of the Duchenne muscular dystrophy locus. *Cell* 1987;51:919-28.
- Jelloun-Dellagi SB, Chaffey P, Hentati F, Ben Hamida C, Tomé FMS, Collin H, *et al.* Presence of normal dystrophin in Tunisian severe childhood autosomal recessive muscular dystrophy. *Neurology* 1990;40:1903.
- Campbell KP, Kahl SD. Association of dystrophin and an integral membrane glycoprotein. *Nature* 1989;338:259-62.
- Ervasti JM, Ohlendieck K, Kahl SD, Gaver MG, Campbell KP. Deficiency of a glycoprotein component of the dystrophin complex in dystrophic muscle. *Nature* 1990;345:315-9.
- Yoshida M, Ozawa E. Glycoprotein complex anchoring dystrophin to sarcolemma. *J Biochem* 1990;108:748-52.
- Ervasti JM, Campbell KP. Membrane organization of the dystrophin-glycoprotein complex. *Cell* 1991;66:1121-31.
- Ibraghimov-Beskrovnyaya O, Ervasti JM, Leveille CJ, Slaughter CA, Sernett SW, Campbell KP. Primary structure of dystrophin-associated glycoproteins linking dystrophin to the extracellular matrix. *Nature* 1992;355:696-702.
- Roberds SL, Anderson RD, Ibraghimov-Beskrovnyaya O, Campbell KP. Primary structure and muscle-specific expression of the 50-kDa dystrophin-associated glycoprotein (adhelin). *J Biol Chem* 1993;268:23739-42.
- Ervasti JM, Campbell KP. A role for the dystrophin-glycoprotein complex as a transmembrane linker between laminin and actin. *J Cell Biol* 1993;122:809-23.
- Hemmings L, Kuhlmann PA, Critchley DR. Analysis of the actin-binding domain of α -actinin by mutagenesis and demonstration that dystrophin contains a functionally homologous domain. *J Cell Biol* 1992;116:1369-80.
- Levine BA, Moir AJD, Patchell VB, Perry SV. Binding sites involved in the interaction of actin with the N-terminal region of dystrophin. *FEBS Lett* 1992;298:44-8.
- Matsumura K, Tomé FMS, Collin H, Azibi K, Chaouch M, Kaplan J-C, *et al.* Deficiency of the 50K dystrophin-associated glycoprotein in severe childhood autosomal recessive muscular dystrophy. *Nature* 1992;359:320-2.
- Azibi K, Bachner I, Beckmann JS, Matsumura K, Hamouda E, Chaouch M, *et al.* Severe childhood autosomal recessive muscular dystrophy with the deficiency of the 50 kDa dystrophin-related glycoprotein maps to chromosome 13q12. *Hum Mol Genet* 1993;2:1423-8.
- Fardeau M, Matsumura K, Tomé FMS, Collin H, Leturcq F, Kaplan J-C, *et al.* Deficiency of the 50 kDa dystrophin associated glycoprotein (adhelin) in severe autosomal recessive muscular dystrophies in children native from European countries. *C R Acad Sci III* 1993;316:779-804.
- Passos-Bueno MR, Oliveira JR, Bakker E, Anderson RD, Marie SK, Vainzof M, *et al.* Genetic heterogeneity for Duchenne-like muscular dystrophy (DLMD) based on linkage and 50 DAG analysis. *Hum Mol Genet* 1993;2:1945-7.
- Romero NB, Tomé FMS, Leturcq F, Kerch FE, Azibi K, Bachner L, *et al.* Genetic heterogeneity of severe childhood autosomal recessive muscular dystrophy with adhalin (50 kDa dystrophin-associated glycoprotein) deficiency. *C R Acad Sci III* 1994;317:70-6.
- Sewry CA, Sansome K, Matsumura K, Campbell KP, Dubovitz V. Deficiency of the 50 kDa dystrophin-associated glycoprotein and abnormal expression of utrophin in two South Asian cousins with variable expression of severe childhood autosomal recessive muscular dystrophy. *Neuromuscul Disord* 1994;4:121-9.
- Zatz M, Matsumura K, Passos-Bueno MR, Pavanello RCM, Marie SK, Campbell KP. Assessment of the 50-kDa dystrophin-associated glycoprotein in Brazilian patients with severe childhood autosomal recessive muscular dystrophy. *J Neurol Sci* 1994;123:122-8.
- Ben Othmane K, Ben Hamida M, Pericak-Vance MA, Ben Hamida C, Blel S, Carter SC, *et al.* Linkage of Tunisian autosomal recessive Duchenne-like muscular dystrophy to the pericentromeric region of chromosome 13q. *Nature Genet* 1992;2:315-7.
- Roberds SL, Leturcq F, Aliamand V, Piccolo F, Jeanpierre M, Anderson RD, *et al.* Missense mutations in the adhalin gene linked to autosomal recessive muscular dystrophy. *Cell* 1994;78:625-33.
- Ohlendieck K, Matsumura K, Ionasescu VV, Towbin JA, Bosch EP, Weinstein SL, *et al.* Duchenne muscular dystrophy: deficiency of dystrophin-associated proteins in the sarcolemma. *Neurology* 1993;43:795-800.
- Engel J. Structure and function of laminin. In: Rohrbach DH, Timpl R, editors. Molecular and cellular aspects of basement membranes. San Diego: Academic Press, 1993:147-77.
- Tryggvason K. The laminin family. *Curr Opin Cell Biol* 1993;5:877-82.
- Paulsson M. Laminin and collagen IV variants and heterogeneity in basement membrane composition. In: Rohrbach DH, Timpl R, editors. Molecular and cellular aspects of basement membranes. San Diego: Academic Press, 1993:177-187.
- Ehrig K, Leivo I, Argraves WS, Ruoslahti E, Engvall E. Merosin, a tissue-specific basement membrane protein, is a laminin-like protein. *Proc Natl Acad Sci USA* 1990;87:3264-8.
- Sanes JR, Engvall E, Butkowski R, Hunter DD. Molecular heterogeneity of basal laminae. Isoforms of laminin and collagen IV at the neuromuscular junction and elsewhere. *J Cell Biol* 1990;111:1685-99.
- Higuchi I, Yamada H, Fukunaga H, Iwaki H, Okubo R, Nakagawa M, *et al.* Abnormal expression of laminin suggests disturbance of sarcolemma-extracellular matrix interaction in Japanese patients with autosomal recessive muscular dystrophy deficient in adhalin. *J Clin Invest* 1994;94:601-6.
- Gee SH, Blacher RW, Douville PJ, Provost PR, Yurchenco PD, Carbonetto S. Laminin-binding protein 120 from brain is closely related to the dystrophin-associated glycoprotein, dystroglycan, and binds with high affinity to the major heparin binding domain of laminin. *J Biol Chem* 1993;268:14972-80.
- Hunter DD, Shah V, Merlie JP, Sanes JR. A laminin-like adhesive protein concentrated in the synaptic cleft of the neuromuscular junction. *Nature* 1989;338:229-34.

37. Hayashi Y, Engvall E, Arikawa-Hirasawa E, Goto K, Koga R, Nonaka I, *et al.* Abnormal localization of laminin subunits in muscular dystrophies. *J Neurol Sci* 1993;119:53-64.
38. Tomé FMS, Evangelista T, Leclerc A, Sudana Y, Manole E, Estournet B, *et al.* Congenital muscular dystrophy with merosin deficiency. *C R Acad Sci III* 1994;317:351-7.
39. Matsumura K, Nonaka I, Campbell KP. Abnormal expression of dystrophin-associated proteins in Fukuyama-type congenital muscular dystrophy. *Lancet* 1993;341:521-2.
40. Mayer U, Nischt R, Poschl E, Mann K, Fukuda K, Gerl M, *et al.* A single EGF-like motif of laminin is responsible for high affinity nidogen binding. *EMBO J* 1993;12:1879-85.
41. Dickson G, Azad A, Morris GE, Simon H, Noursadeghi M, Walsh FS. Co-localization and molecular association of dystrophin with laminin at the surface of mouse and human myotubes. *J Cell Sci* 1992;103:1223-33.
42. Reing J, Durkin ME, Chung AE. Laminin B1 expression is required for laminin deposition into the extracellular matrix of PC12 cells. *J Biol Chem* 1992;267:23143-50.
43. Brown JC, Wiedemann H, Timpl R. Protein binding and cell adhesion properties of two laminin isoforms (AmB1eB2e, AmB1sB2e) from human placenta. *J Cell Sci* 1994;107:329-38.
44. Arahata K, Hoffman EP, Kunkel LM, Ishiura S, Tsukahara T, Ishihara T, *et al.* Dystrophin diagnosis: comparison of dystrophin abnormalities by immunofluorescence and immunoblot analyses. *Proc Natl Acad Sci USA* 1989;86:7154-8.
45. Arahata K, Ishihara T, Kamakura K, Tsukahara T, Ishiura S, Baba C, *et al.* Mosaic expression of dystrophin in symptomatic carriers of Duchenne's muscular dystrophy. *N Engl J Med* 1989;320:138-42.
46. Arikawa E, Ishihara T, Nonaka I, Sugita H, Arahata K. Immunohistochemical analysis of dystrophin in congenital muscular dystrophy. *J Neurol Sci* 1991;105:79-87.
47. Matsumura K, Nonaka I, Tomé FMS, Arahata K, Collin H, Leturcq F, *et al.* Mild deficiency of dystrophin-associated proteins in Becker muscular dystrophy patients having in-frame deletions in the rod domain of dystrophin. *Am J Hum Genet* 1993;53:409-16.
48. Matsumura K, Tomé FMS, Ionasescu VV, Ervasti JM, Anderson RD, Romero NB, *et al.* Deficiency of dystrophin-associated proteins in Duchenne muscular dystrophy patients lacking C-terminal domains of dystrophin. *J Clin Invest* 1993;92:866-71.
49. Matsumura K, Burghes AHM, Mora M, Tomé FMS, Morandi L, Cornello F, *et al.* Immunohistochemical analysis of dystrophin-associated proteins in Becker/Duchenne muscular dystrophy with huge in-frame deletions in the NH₂-terminal and rod domains of dystrophin. *J Clin Invest* 1994;93:99-105.
50. Matsumura K, Campbell KP. Dystrophin-glycoprotein complex: its role in the molecular pathogenesis of muscular dystrophies. *Muscle Nerve* 1994;17:2-15.